



<http://www.natsca.org>

Journal of Natural Science Collections

Title: Wrestling with the Yatiantota Tusker: Cleaning, conserving and mounting an intriguing Asian elephant skeleton

Author(s): Larkin, N. R.

Source: Larkin, N. R. (2018). Wrestling with the Yatiantota Tusker: Cleaning, conserving and mounting an intriguing Asian elephant skeleton. *Journal of Natural Science Collections*, Volume 5, 98 - 109.

URL: <http://www.natsca.org/article/2443>

NatSCA supports open access publication as part of its mission is to promote and support natural science collections. NatSCA uses the Creative Commons Attribution License (CCAL) <http://creativecommons.org/licenses/by/2.5/> for all works we publish. Under CCAL authors retain ownership of the copyright for their article, but authors allow anyone to download, reuse, reprint, modify, distribute, and/or copy articles in NatSCA publications, so long as the original authors and source are cited.

Wrestling with the Yatiantota Tusker: Cleaning, conserving and mounting an intriguing Asian elephant skeleton

Nigel R. Larkin

Cambridge University Museum of Zoology, Downing St, Cambridge, CB2 3EJ

nrlarkin@easynet.co.uk

Received: 31/07/2017

Accepted: 24/10/2017

Citation: Larkin, N.R., 2018. Wrestling with the Yatiantota Tusker: Cleaning, conserving, and mounting an intriguing Asian elephant skeleton. *Journal of Natural Science Collections*, 5, pp.98-109.

Abstract

Cambridge University Museum of Zoology underwent refurbishment between 2013 and 2017 as part of a wider redevelopment project. As well as cleaning and conserving the specimens that were already on display, the opportunity was taken to conserve, remount and re-display some specimens from the collections that had been in storage for years. The most significant and problematic of these was the skeleton of a large male Asian elephant. The specimen has an interesting history, having killed many people in Sri Lanka before being shot in 1881, and in the 1960s the skeleton was used as set-dressing for an iconic science fiction film. The bones were successfully cleaned using Synperonic A7 in deionised water, with acetone added as required for the grimeiest areas. The metalwork for the skeleton had been missing for decades, so a new mount had to be made from scratch. This involved a variety of skills, including blacksmithing, welding and engineering processes, and therefore had to be undertaken offsite in a suitably large conservation facility, involving transporting the skeleton by road. The Asian elephant skeleton is now back on display next to the skeleton of the African elephant, so that they can be compared. The skeleton exhibits very obvious pathological deformation in many of the bones, providing a particularly engaging exhibit.

Keywords: *Elephas maximus*; Osteology; Rogue; Pathology; 2001 Space Odyssey

Introduction

Cambridge University Museum of Zoology underwent refurbishment between 2013 and 2017 as part of a wider redevelopment project. The six-storey 1960s Arup Building in which the museum was located required complete refurbishment, after which the rest of building would form part of the 'Cambridge Conservation Initiative'; a unique collaboration between the University of Cambridge and the Cambridge-based cluster of leading

biodiversity conservation organisations. The incidental and unavoidable complete refurbishment of the University's Museum of Zoology meant that exciting new displays could be planned, as well as the re-interpretation of old specimens and the display of some material that had not been on show for a while, or had never been displayed before. The skeleton of a large male Asian elephant (*Elephas maximus* Linnaeus, 1758; UMZC.H.4611) had been on display in the old museum from 1865 to 1965, but had lain in storage



© by the author, 2018. Published by the Natural Sciences Collections Association. This work is licensed under the Creative Commons Attribution 4.0 International License. To view a copy of this license, visit: <http://creativecommons.org/licenses/by/4.0/>.

for almost 50 years. The redevelopment project seemed an ideal opportunity to put the Asian elephant skeleton back on display alongside the African elephant skeleton (*Loxodonta africana* (Blumenbach, 1797); UMZC. H.4451), similar to how they had been displayed in the past (Figure 1).

History of the specimen

The Asian elephant skeleton had last been seen by the public when it was used as set dressing for iconic scenes in the 1968 epic science fiction film *2001: A Space Odyssey* by Stanley Kubrick and Arthur C. Clarke (Lowe, 2014). Early on in the film, when primates are seen living in an African landscape, many of the bones scattered around the set are from this particular elephant skeleton.




Figure 1. The two elephant skeletons on display in the 'Old Zoology Museum' at Cambridge University. The Asian elephant (UMZC.H.4611) on the left, the African elephant (UMZC.H.4451) on the right. Image: Cambridge University Museum of Zoology.

The specimen has another claim to fame, however. The elephant was shot in 1881, as it was damaging crops and killing people in Ceylon (now Sri Lanka). The only information the museum held about the specimen was the transcription (Shiple, 2011) of an entry made in a notebook by the controversial civil servant (Powell, 2010) C.J.R. Le Mesurier, who was sent to shoot the elephant:

"The Yatiantota Tusker, a notorious and proscribed rogue elephant (bull), that had done much damage to life and property. It was shot on 6th February 1881, at Yakkela Kele ("forest of the devil's stream"), near Malalpola, eight miles from Ruanwela, in the Kegalle district, Western Province, Ceylon. Height, 9 feet; tusks, 4 feet 11½ inches, and 4 feet 10 inches outside curve - weight 75lbs." (Shiple, 2011: p.281)

With the exception of the tusks, which were retained as a trophy, the elephant skeleton was presented to the Museum of Zoology in 1882 by Sir John Phear MA, Chief Justice of Ceylon, after being prepared and packed by the taxidermist of the Colombo Museum (Shiple, 2011).

At the Natural Sciences Collections Association (NatSCA) conference in 2017, themed 'Provocative new ways of working with collections', Subhadra Das (UCL Culture) and Miranda Lowe (Natural History Museum, London) presented a thought-provoking talk titled '*Nature read in black and white; or, How to stop being racist and develop worthwhile natural history curation*'. They pointed out that a significant proportion of specimens in natural history collections in British museums had been collected during the time of the British Empire. Methods of acquisition were varied but many would have directly reflected aspects of colonisation or even slavery. However, such histories are rarely explored in museum narratives, which mostly focus on scientific discovery and advancement. Das and Lowe suggested that, by giving such specimens a purely scientific interpretation, museums were not only ignoring an important part of each specimen's context but were effectively creating barriers to source or diaspora communities, potentially leading to the alienation of these communities from museums. They recommended that one way to improve understanding of the context in which specimens were acquired would be for natural science curators to engage historians specialising in the relevant time period, preferably those indigenous to the geographical area under discussion, to assist with creating an appropriate narrative for the display (Das and Lowe, 2017).

However, attempting to recover information about a specific specimen – even one as notorious as this elephant – after such a long period of time has elapsed is not necessarily straightforward or successful. Several members of staff at the Natural History Museum in Sri Lanka were contacted to ask if any contemporary accounts or other information relating to the murderous 'Yatiantota Tusker' existed but, despite repeated attempts at contact, no response was received. Reports from the time might have told us who had been injured or killed by the elephant, giving names to replace the vague "*much damage to life and property*". The perspective of families left behind after these encounters would have given invaluable context. Not least because now, over 100 years later, between 30 and 50 people

a year are killed by elephants in Sri Lanka due to increases in the human population and subsequent changes to land use patterns, reducing the natural elephant habitat and inevitably generating conflict (Bandara and Tisdell, 2002; Santiapillai et al., 2010).

Extensive searching on the internet uncovered a little more detail about the Yatiantota Tusker, found in a scanned version of an out of print book from 1894 that has only been available online since 2007. Typically, it is from the perspective of a British trophy hunter, but these few words themselves are telling, as it may be that the rogue was killed as much for its unusually large tusks (almost 5 feet in length) as to stop it from killing indigenous people. At least this account puts a minimum number on the victims:

"The Ceylon elephants have no tusks, the bulls sometimes developing tusks about a foot long. During a seven years' residence in Ceylon I never heard of but one tusker, the celebrated Yatiantota rogue, which was killed by two friends of mine after a struggle lasting many hours. During his career this elephant had certainly killed a score of human beings. His appearance may be familiar to the reader as his fore-part, beautifully mounted by Ward, formed the central object in the Ceylon Court at the Indian and Colonial Exhibition." (Snaffle, 1894: p.174-175)

Upon examining the skeleton, one possible reason why this animal was dangerous becomes clear: its left ulna seems to have been broken at some point during the animal's lifetime, and it certainly became badly infected, fusing to the radius. The consequent severe pathological deformation of the bone is very obvious (Figure 2). The animal would clearly have been disabled and in pain. Other, possibly associated, pathologies in the skeleton are also obvious: the symphysis of the mandible swells distally and is porous and asymmetrical, which is abnormal (Figure 3); there are also abnormal bone growths on the proximal end of the left humerus and in the first left rib, and in the left scapula; and some of the vertebrae are asymmetrical, with bony overgrowths clearly visible ventral to two vertebrae (Figure 4). The fact that this animal was suffering from what must have been a painful and debilitating injury and then subsequent disease may well have led it to become a dangerous 'rogue' elephant, apparently killing at least 20 people.

Cleaning, conserving and mounting the skeleton

The skeleton was dirty from being in storage for 50 years, most recently laying uncovered on open racking. Many bone surfaces were sticky with residues of natural oil, and therefore dust and dirt had adhered to these areas, turning them black over time.

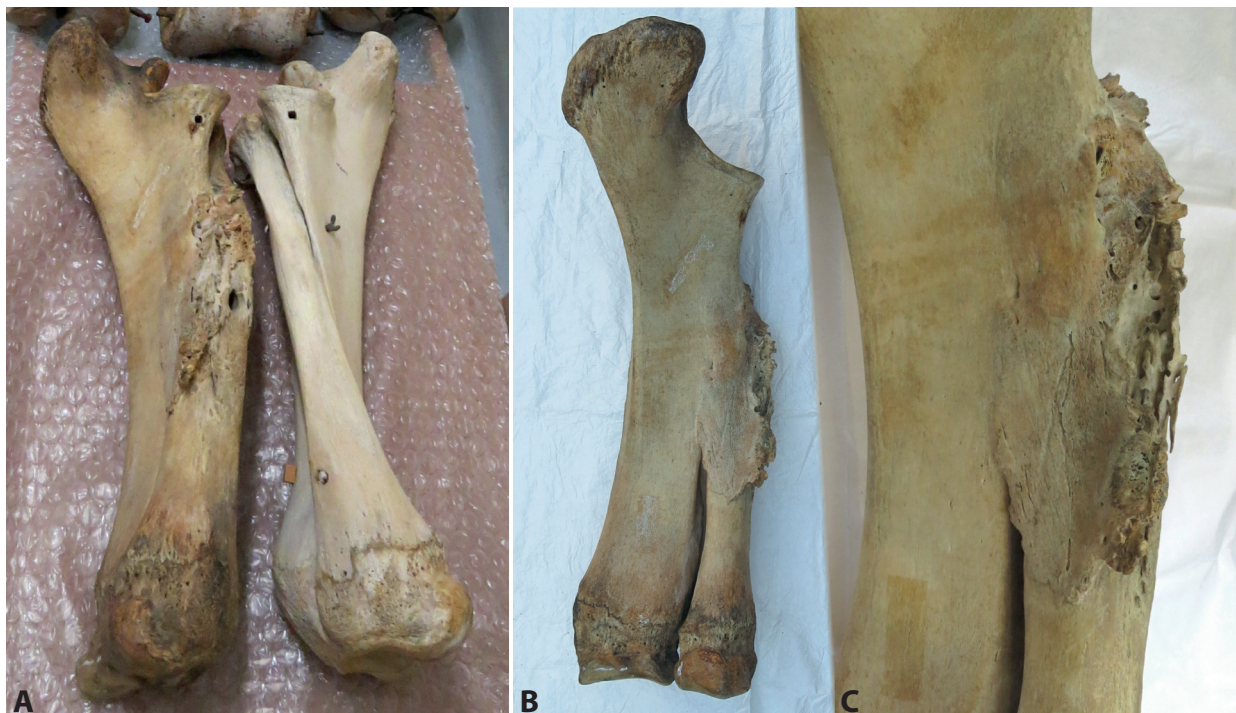

Figure 2. A. The radius and ulna of both of the forelimbs of UMZC.H.4611, showing the pathologically deformed left radius and ulna to the left of the image clearly different to the right radius and ulna on the right of the image; B. the fused left radius and ulna, showing the area of deformed bone; C. a close-up of the diseased area of the left ulna. Image: Nigel Larkin.

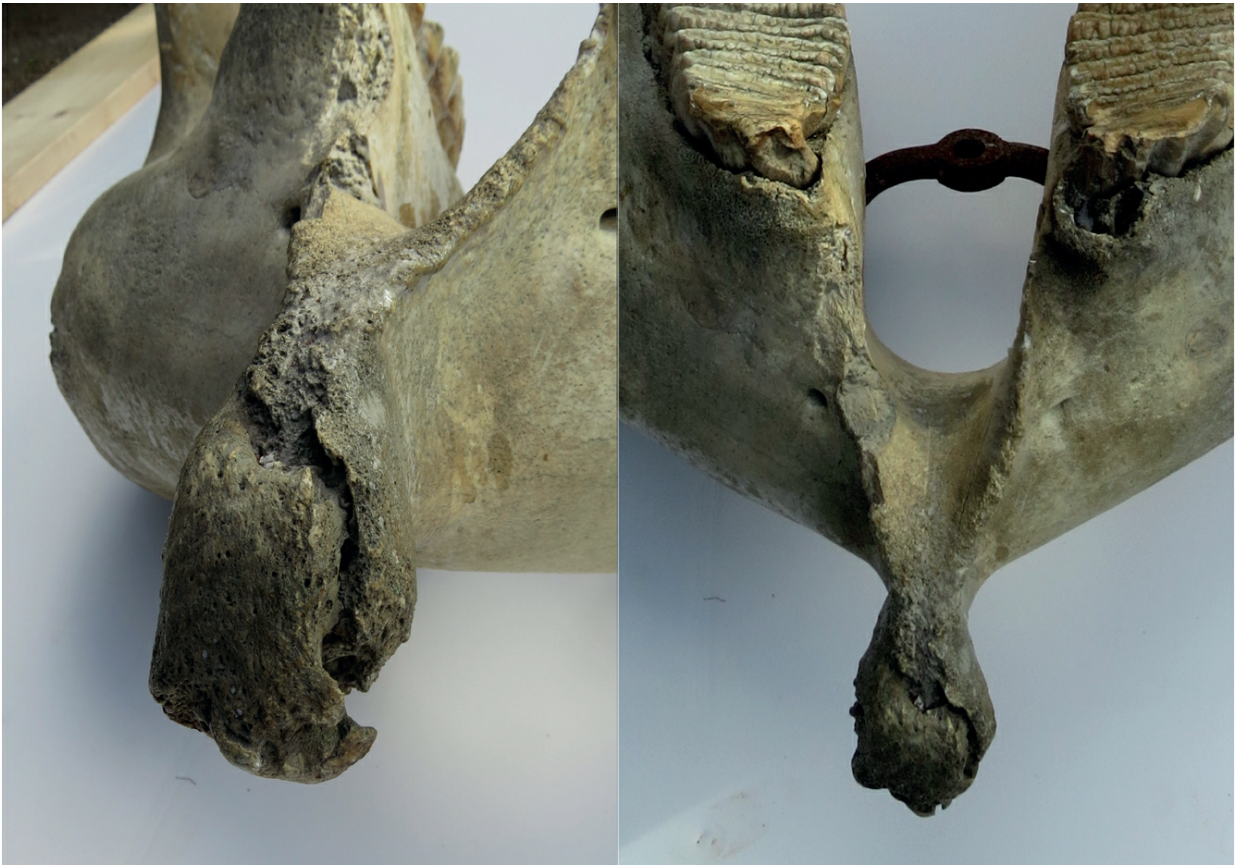

Figure 3. The pathologically deformed symphysis of the mandible of UMZC.H.4611. Image: Nigel Larkin.

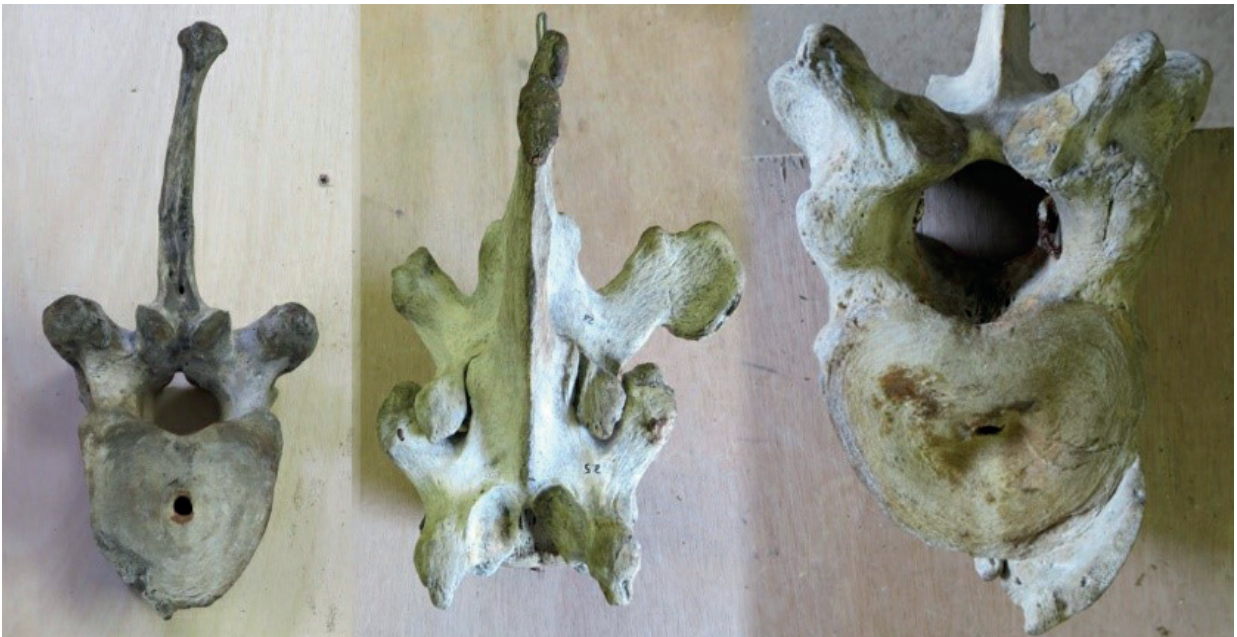

Figure 4. Pathologically deformed vertebrae of the Asian elephant skeleton (UMZC.H.4611): two asymmetrical vertebrae and on the far right a vertebra with a bony overgrowth ventral to the centrum. Image: Nigel Larkin.

This dirt had to be removed along with chalk marks, small splatters of paint, and scuff marks from the movement and storage of the specimen over time (Figure 5). None of the original metal mount survived the loan to MGM studios in 1967, except the bar on which the vertebrae were threaded and some of the small brackets that held the limb bones together. Therefore, the skeleton had to be mounted from scratch with a new purpose-made metal armature. As the specimen was of historical significance, where possible it was mounted in the same way as before, so that old holes drilled into the bones could be reused, rather than drilling new holes in the specimen. Unfortunately, only a single photo was available of the skeleton mounted in the old museum, and little of the original mount could be observed. Therefore, the mount of the African elephant skeleton on display was used as a guide. All conservation and cleaning techniques and materials used during the project were as minimally invasive as possible. Adhesives and consolidants used were stable and reversible, and all processes and materials used were recorded.

Cleaning

The bones were cleaned first with dry soft brushes next to the hose of a vacuum cleaner (covered with gauze) to remove the loose debris and dust. Ingrained deposits were cleaned with Synperonic A7 in deionised water. Synperonic A7 is an alcohol ethoxylate, a mild non-ionic detergent. Synperonic has been widely used by conservators in museums for decades as a standard conservation product to

clean particularly dirty osteological specimens and other material. It can be used as a detergent, wetting agent, non-ionic surfactant, and an emulsifying and dispersing agent (Hackney et al., 1990; McCutcheon's, 2003).

A 2% solution of Synperonic A7 in deionised water was applied to small areas of bone at a time with a soft brush, then wiped away immediately with a lint-free paper towel. The area was then brushed with deionised water and immediately dried again with a paper towel, and this 'rinsing' was repeated immediately a second time. It was important not to let the areas dry out completely between applications, to avoid repeated cycles of wetting and drying. The dirtiest areas, particularly the patches of black, greasy bone, were cleaned in a similar fashion but with acetone added (1 part acetone to 3 parts Synperonic A7 solution), applied with stiffer brushes.

Whilst dry methods of cleaning bone (such as smoke sponges and 'groom sticks' made of natural rubber and air) are less invasive than wet methods, they may not clean a specimen as effectively, especially if the bone surfaces are rough, like those of an elephant bone. There is a small element of risk to the process: even though the area cleaned is 'rinsed' with deionised water a couple of times immediately after applying the detergent, there is no guarantee that the detergent will be entirely removed. Also, multiple applications of water over a period of time can damage molecular bonds within bone and ultimately exacerbate deterioration. However, a wet cleaning

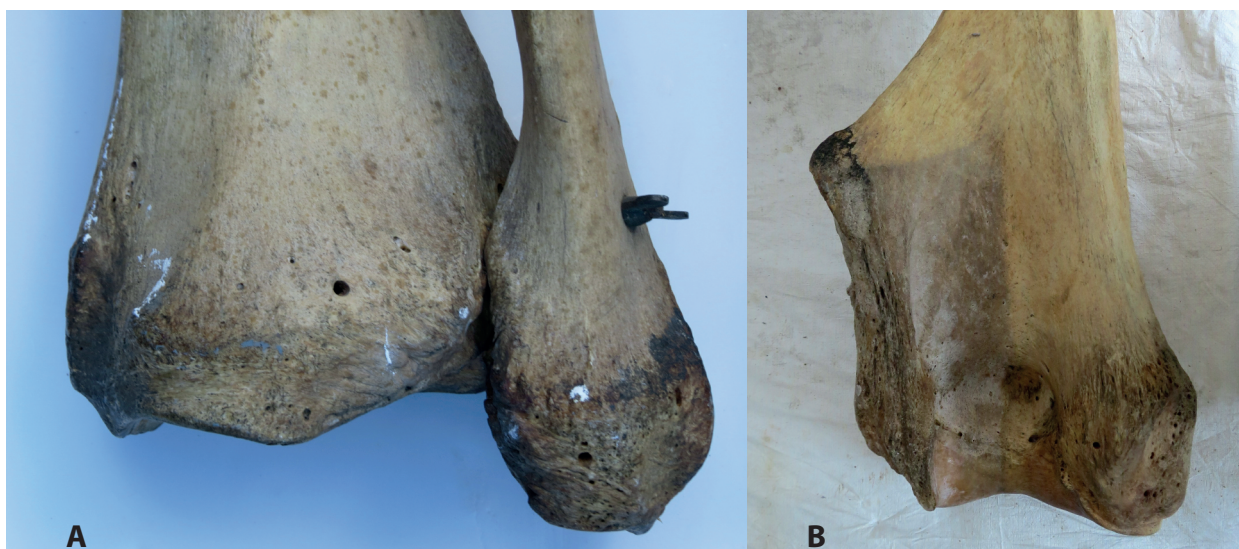

Figure 5. Examples of how dirty the bones of UMZC.H.4611 were before cleaning A. Paint and chalk marks etc on very dirty limb bones. B. A humerus mostly cleaned but the lower left section still dirty. Image: Nigel Larkin.

treatment is rarely required, and should be limited only to specimens that are extremely dirty.

Old temporary labels made from 'sticking plaster' roll (as used in first aid) stating 'left humerus' or 'right scapula' etc, from when the skeleton had been dismantled in the 1960s, were removed gently with a scalpel, as they were redundant. Where small breaks in bones had been repaired in the past, some excess adhesive (possibly protein colloid 'animal glue') had spilled out onto the surfaces of the surrounding bone. This was unsightly and was easily removed with scalpels. The glue within the breaks was stable and did not require removing and replacing. In many places, a white waxy substance was lying on the surface of the bone in patches, ranging in depth from a paper-thin film to a thick deposit up to 4 or 5mm deep, particularly on the skull. This was largely removed with thin wooden spatulas and stiff brushes, before final cleaning with Synperonic A7. The substance remains unidentified, but it is possible that it was a temporary water-soluble putty such as that sometimes used when preparing a specimen for moulding (Rixon, 1976), although there is no record or recollection of the skull or other bones having been replicated. When the skeleton was being used during the filming of *2001: A Space Odyssey* at MGM studios in 1967, almost all of the metal mount was lost. It is possible that the bones were interfered with whilst on loan, and this waxy substance may date to this period.

Although all the bones have been cleaned, they are not a uniform colour. They have a natural variation, but also the lower right forelimb (foot, radius and ulna) is much lighter in colour than the rest of the skeleton (Figure 2), despite all the cleaning undertaken on the other bones. This forelimb was on display in the museum from the 1970s until 2013, and whilst it is possible that the bones had been artificially whitened for display, there are no records of this process. A more likely explanation is that the bone colour faded over time due to the lighting conditions (Cassman et al., 2006). Several other specimens on display in the museum during this time suffered the same fate. The rest of the elephant skeleton could be treated to make the bones lighter to match the right forelimb, but this would have been an unnecessary, and potentially damaging, invasive procedure. In the past, chlorine bleach has been used to whiten skeletons, even though this can degrade the structure of bone long after the treatment (Mori, 1979; Fenton et al., 2003). Hydrogen peroxide has also been used and, whilst this is less deleterious than

chlorine bleach, it is still an invasive and potentially damaging process.

Conservation and mounting

The new metal mount had to be designed and made in a way that would allow the specimen to be fully mounted in the author's conservation studio in Shropshire and then disassembled and transported safely to the museum in Cambridge, where it would be assembled again. As the specimen's permanent display position would be on top of a wheeled plinth about 1m high, which would need to be moved occasionally, the skeleton's metal mount needed to be particularly strong, rigid, and secure.

The metal bar that the vertebrae had been stored on for at least the last 50 years was the only substantial piece of the original mount that survived the loan to MGM Studios for filming. This bar is T-shaped in cross-section and runs through the neural arch of each vertebra. It was thick with rust and bent at one end, presumably from poor handling. However, as the rust was easily removed with a flap-disk of sandpaper on an angle grinder and the bar could be straightened after heating on a forge, there was no need to replace it. It had rusted simply because it had never been painted. This metal bar and all other new metalwork was painted to prevent rust forming, using 'Ivory' coloured acrylic aerosol spray for metals with a matt finish, to match the colour of the bones.

A separate, thin metal rod ran the length of the spine through a small hole in each of the vertebral centra. This had rusted and was stuck firmly within the bones (Figure 6). This rod had to be cut into sections between the vertebrae so that the bones could be slid off the main vertebral bar one by one, after which the pieces of rusty rod could be removed. The thin rod was replaced with a new steel rod that was heated and bent to the curvature of the spine. It was slightly thinner than the original, to ensure it would slide through the holes in the vertebrae more easily.

In the single old photograph that shows the skeleton as it was previously mounted (Figure 1), it can be seen that only two upright supports were used, one under the pelvis and one under the neck. The skull would have been inserted onto the end of the vertebral bar via the foramen magnum, with a hook attaching the rear of the skull to the atlas vertebra. However, there are severe cracks in the rear of the skull around the occipital foramen (Figure 7). This area would have taken the strain of the weight of the skull, mandible, and tusks in its previous mounted position, and it

seems to have suffered damage as a result. The cracks in the skull were not treated, as there was no loose material, and filling the cracks would have been merely cosmetic. The integrity of the rear of the skull had been compromised, and it therefore could not be mounted in the same way without suffering further damage. For this reason, and because the skeleton would need to be moved around the gallery occasionally on the plinth without swaying, a third upright support was required specifically to take the weight of the skull, mandible, and tusks from below.

Three steel tubes (22 mm internal diameter) were cut to fit i) under the pelvis, ii) between the front legs, and iii) underneath the skull. Each of these was a different height. A section of threaded steel bar (22 mm diameter) was inserted into each of the lower sections of these tubes, protruding by several inches, and was MIG (Metal Inert Gas) welded into place at the end of the tube. A steel 'floor plate' was then welded to the base of each tube to form a collar that would sit on the top of the wooden plinth (Figure 8), with four holes in the horizontal surface so that it could be screwed to the top of the plinth. The threaded bar in the lower end of each tube inserted into a hole drilled through the plinth under the pelvis, pectoral girdle, and skull, in line with the vertebral bar. On the underside of the plinth, these threaded bars inserted through a large, flat steel bracket, designed to reduce the ability of the upright poles to lean sideways. The threaded bar was secured on the other side of this bracket with nuts and spring

washers. This provided three very secure, robust upright vertical supports to take the weight of the vertebrae, ribs, skull, tusks, mandible, and humeri. A long, thin, steel bracket was made to hold the rear and middle upright tubes together, shaped to fit the contour of the underside of the vertebrae.

By heating and shaping lengths of flat steel bar on a forge and welding them together on top of a short steel rod, a bespoke bracket was made to fit the underside of the sacral block and adjoining vertebrae, so that the pelvis was held comfortably on top of the rear upright tube, with the vertical length of rod inserting into the top of the upright tube (Figure 9). A bracket was made in a similar fashion to hold the cervical vertebrae in place on top of the middle pole. A more substantial steel bracket was made to securely hold the skull in place, so that most of the weight of the skull was held by flat steel under the palate, with small brackets either side of the rear of the skull to stop sideways movement, and the hook on the back of the skull connecting to the vertebral bar. All the brackets were lined with white Plastazote foam, a chemically inert, low density, closed cell, cross-linked polyethylene foam of archival quality (Garside and Hanson, 2011), so that none of the bones were sitting directly on metal.

Five of the eight small brackets that hold the lower limb bones to the upper limb bones were missing, and had to be made using a forge, anvil, hammers, and angle grinder (Figure 10). Some of the threaded

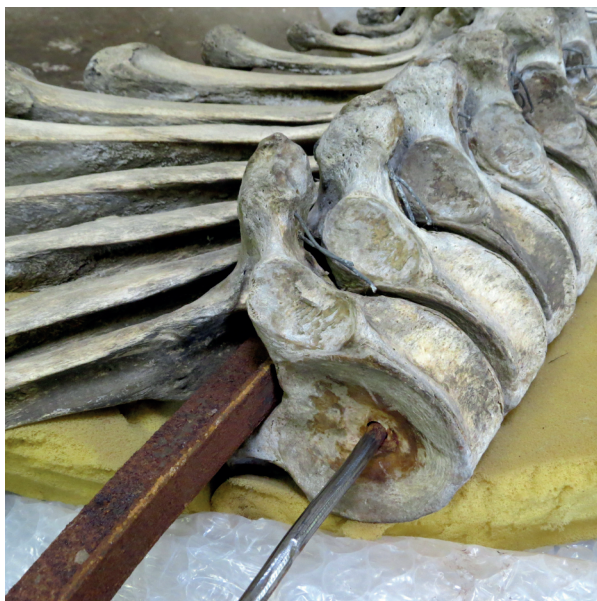

Figure 6. The rusty T-shaped vertebral bar with some of the vertebrae still attached. The thin vertebral rod has been cleaned in an attempt to remove it from the vertebral centra. Image: Nigel Larkin.

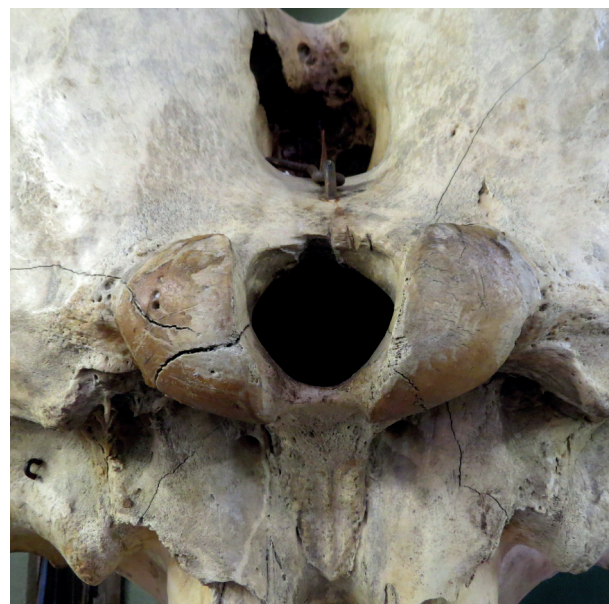

Figure 7. The rear of the elephant skull (UMZC.H.4611) showing substantial cracks around the occipital condyles that have left the skull weak and vulnerable to further damage. Image: Nigel Larkin.



Figure 8. A steel floor plate welded to the bottom of one of the upright steel tubular supports, within which a 22mm diameter threaded bar is welded. This bar runs through the wooden base and is secured underneath with nuts and spring washers. Image: Nigel Larkin.

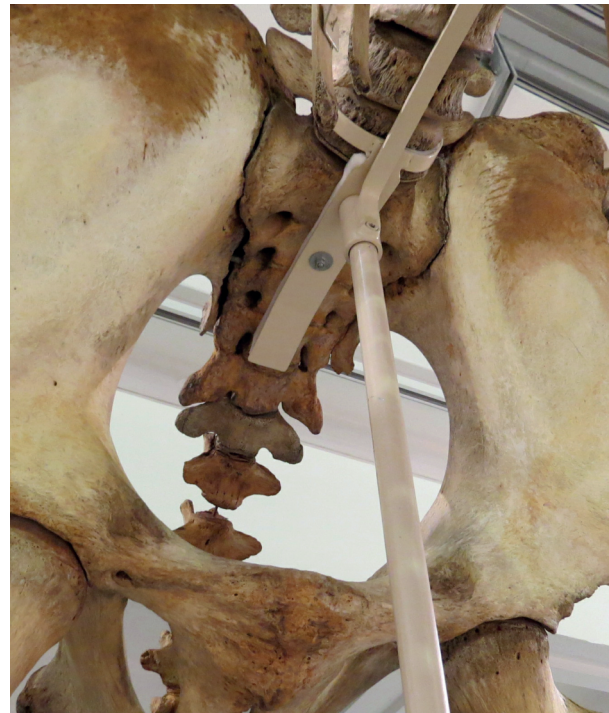

Figure 9. The steel support for pelvic region: the vertical rod on the underside inserted into the top of the rear upright support; and the upper surfaces of the metal bracket are lined with white inert Plastazote foam under the bones. Image: Nigel Larkin.

bars that had been inserted into the ends of the limb bones for attachment to the brackets were missing, and some were present but bent. Therefore, some had to be bent back into position and others replaced.

A horizontal steel rod with a threaded bar welded to either end was made to hold the humeri in position, using the existing wide holes running through the shaft of each bone that had held the previous supports. This rod was attached to the middle upright support with nuts and bolts running through a small, flat plate that was welded to the horizontal bar, securing it to a bracket on the upright tube. The bracket was held in place with a grub screw secured with an Allen key.

Some of the small pieces of original metalwork were very difficult to remove. The bracket on the underside of the mandible was very rusty and needed to be removed for cleaning. The bolts securing the bracket could not be undone, even after WD40 had been carefully applied to the metalwork a few times. Therefore, a small 'pen'-sized blowtorch was used to heat and expand the rusty metal bracket and un-seize it from the bolts, which could then be unscrewed and

removed. The bracket and the bolts were cleaned with wire brushes to remove the rust, and were then painted to match the rest of the metalwork and bones.

Many toe bones were loose and not attached to the otherwise articulated feet. These loose bones had to be identified and re-attached using thin wire (0.8 mm diameter galvanised steel) running through the old holes. Some old, rusty wires holding foot bones together were brittle and had to be replaced. A support was made for each foot, to replace the missing metalwork, consisting of an upright steel tube welded to a steel base plate that could be screwed to the top of the plinth (Figure 11). The metal rod of the bracket for the rear of each foot could then slide into the top of the tube to hold the foot in the correct, upright position.

The strips of cartilage from the sternum and from the distal ends of the ribs had dried and curled up at some point in the past. Despite cleaning with Synperonic A7 followed by experimenting with soaking a few pieces in deionised water for up to two weeks, these could not be straightened. Fortunately,



Figure 10. One of the five brackets made on the forge to hold the lower limb bones in articulation with the upper limb bones. Image: Nigel Larkin.



Figure 11. One of the four supports made for the feet: a steel tube welded to a base plate with screw holes, so it can be secured to the wooden base. Image: Nigel Larkin.

the anterior-most pieces were not too curled, and this enabled most of the sternum bones to be re-attached with the appropriate pieces of cartilage in place, using thin steel wire running through the old holes.

The ribs were reattached to the vertebrae with galvanised steel wire running through the old holes in the rib heads and vertebrae, with the ends of the wires twisted together on the undersides of the ribs. The ribs were secured in place near their distal ends to one long thin strip of steel on each side, bent to the shape of the ribcage. Where possible, old wire holes were used to attach the ribs to the metal strip, but in some instances new holes did need to be drilled. These were the only new holes required in the whole mounting process.

Four ribs that had been broken historically required repair. This was undertaken with Paraloid B72 adhesive, after the edges of the breaks were consolidated with 10% Paraloid B72 solution in acetone. In two instances, plaster of Paris was used to fill gaps where bone was partially missing. Plaster should never be applied directly to bone, and in this instance the Paraloid B72 consolidant that had already been applied formed a barrier layer that also made the edges of the break more secure, providing a better purchase for the plaster. The plaster was painted with artists' acrylic paints to almost, but not quite, match the bone, as a curator, conservator, or researcher will need to be able to see the change in materials.

The two tusks were replicas of the originals, cast in solid plaster when the animal was defleshed circa 1881, and the originals were retained in Sri Lanka as a trophy. Museum records relate that the real tusks of this specimen became available in 1904, but the 180 guinea (£189) asking price was deemed too expensive at the time (Clark, 1904; Le Mesurier 1904). The solid plaster casts of the tusks were stored separately from the skull, and would have added substantially to the weight of the skull once mounted, pulling the front of the skeleton forward. Therefore, the plaster tusks were moulded in silicone rubber to enable lighter, hollow replicas to be made. Many different resins could have been used to make the replicas of the tusks, but Jesmonite acrylic resin was used with fibreglass because, although it can be heavy, it is very strong and could be worked to create details that were missing on the rather blank and unconvincing plaster casts. Also, Jesmonite is easily painted with artists' acrylic paints to good effect.

Replicating the two tusks saved 22kg in total, and they look more realistic than the original plaster casts.

Transport and installation

After the cleaned and conserved skeleton had been fully mounted on its new metal supports in the conservation studio, it was completely dismantled with the exception of the vertebrae and ribcage. Unwiring all the ribs at either end and then wiring them up again in Cambridge would not only have been an unnecessary amount of work, but it would have placed a lot of physical strain on the ribs, particularly the repaired ribs, which are very vulnerable to breakage during handling. Instead, a supporting frame was built around the ribcage using wooden batons, metal brackets, and a central, sturdy beam from which the vertebral column and associated ribcage hung, held in place in all directions with wide cotton slings (Larkin, 2016). The supporting metalwork could then be dismantled, and any remaining bare metal was painted. All the bones and metalwork were packed in acid-free tissue and bubble wrap. The whole skeleton was transported in a single Luton van. The frame holding the ribcage was placed on a foam mattress and secured to the sides and floor of the van with wooden batons, metal brackets and screws. The skull, mandible, tusks, and limb bones were wrapped in acid-free tissue and bubble wrap, and lay on top of foam mattress. They were securely wedged in place with more foam and bubble wrap to prevent movement.

Once at the Museum of Zoology, the skeleton had to be carried downstairs to the lower gallery one element at a time. Carrying specimens up or down stairs should always be avoided wherever possible, but the lifts were refurbished as part of the overall project and, due to overrunning schedules, were yet to be fully commissioned. It took four strong people to carry the ribcage downstairs, carefully manoeuvring it around the corners of the landings. Installing the skeleton on the 1 m high display plinth posed problems. It had been difficult enough putting the skeleton together in the conservation studio, where hoists were used, but there were no hoists available in the museum gallery. The tops of the three upright supporting metal tubes on which the vertebral column and skull had to be positioned were now about 10 feet from the floor. Although a couple of museum 'stackers' (manually operated fork lift trucks used for moving specimens in museum stores) were available, they did not reach high enough to facilitate getting the vertebral column and ribcage in place. Therefore, the wooden base for the specimen

was taken off the display plinth and put back on to the floor, and the ribcage was manoeuvred into position using the two stackers to lift either end of the metalwork. Once the ribcage was secured to the upright supports, the stackers were lowered and used to pick up the wooden base at either end. The wooden base, with the metal supports and ribcage in place, was then raised just above the display plinth and carefully slid into position. All the limb bones were mounted to provide stability to the skeleton before the skull was mounted. To undertake this, surplus wooden crates were covered with Plastazote foam and carefully secured to the stacker platform to make up the height required to get the heavy skull into position. The skull was lifted manually onto the crates on the stacker, and was secured in place temporarily with straps. It was lifted into position and secured on its supporting mount with its original metal hook. Once the skull was secure, the mandible, tusks, and tail were secured in place (Figure 12). The murderous 'Yatiantota Tusker', the "*notorious and proscribed rogue*" once more dominated the museum.



Figure 12. The Asian elephant skeleton (UMZC.H.4611) installed on the high plinth, in the gallery still undergoing refurbishment. Image: Nigel Larkin.

Conclusions

Cleaning the very dirty bones was successfully undertaken using Synperonic A7, with acetone as required. The work could not have been undertaken without using a very large conservation studio facility where hoists could be deployed. Blacksmithing, welding, and engineering skills were essential, as well as a knowledge of anatomy and osteological

conservation. Whilst all the elements of this large skeleton were transported by road some distance to the conservation studio and back, and required a great deal of manual handling when being cleaned and mounted, not a single piece was damaged. The cleaning, conservation, and mounting of the bones, including replicating the tusks and installing the skeleton in the gallery, took approximately four months' work in total.

To have an Asian elephant on display next to an African elephant skeleton is a fantastic and educational sight, enabling direct comparison between the two species, and is entirely in keeping with the history of this museum. That the Asian elephant skeleton has such an interesting history - from disability and disease through the ensuing murderous incidents to appearing in a classic cult science fiction film - is unusual, and this can be explored in many ways, engaging different demographics. In particular, the pathological deformation evident in the bones is sure to fascinate visitors for generations to come. As it currently stands, however, the story of the collection of this particular specimen is typical of such events during the British Empire: despite at least 20 people apparently being killed by the animal, this barely warrants a mention in either of the two contemporary sources. Both accounts focused on the size of the animal and the trophy-worthiness of the tusks rather than on the lives that had been lost.

It is clear that the sometimes-uncomfortable story of how and why many natural history specimens were collected during the time of the British Empire is underreported in museum displays. This can be partly due to the lack of detailed information in museum records, rather than a deliberate curatorial choice. However, the lack of detail can be an interesting story in itself, highlighting the preoccupations and prejudices of the time. As more old and rare books and journals are scanned and uploaded to the internet, information about individual specimens or the collectors involved becomes more readily available. Working with historians and relevant colleagues overseas in the areas from which specimens were sourced should further improve information on historical context, and some interesting stories will no doubt be uncovered in the process.

Acknowledgements

Thanks are due to: members of staff at Cambridge University Museum of Zoology (especially Matt Lowe and Polly Hodgson) for organising the funding of the project, providing some of the history of the specimen and for assistance with loading and unloading the skeleton; Ruth Murgatroyd for assistance with the final assembly of the bones in the gallery; the Pilgrim Trust who funded the project; and to anonymous reviewers of this paper.

References

- Bandara, R. and Tisdell, C., 2002. Asian elephants as agricultural pests: economics of control and compensation in Sri Lanka. *Natural Resources Journal*, 42(3), pp.491-519.
- Cassman, V., Odegaard, N., and Powell, J. (eds.), 2006. *Human remains: guide for museums and academic institutions*. Lanham, MD: Rowman Altamira.
- Clark, J.W., 1904. *Memo from John Willis Clark to Sidney Harmer dated 1904-03-11*. [manuscript] 2:268Q. Cambridge, Cambridge University Museum of Zoology Archives.
- Das, S. and Lowe, M., 2017. *Nature read in black and white or How to stop being racist and develop worthwhile natural history curation*. Talk given at the Natural Sciences Collections Association conference 'Provocative new ways of working with collections', Cambridge University Museum of Zoology, April 2017.
- Fenton, T.W., Birkby, W.H., and Cornelison J., 2003. A fast and safe non-bleaching method for forensic skeletal preparation. *Journal of Forensic Sciences*, 48(1), pp.1-3.
- Garside, P. and Hanson, L., 2011. A Systematic Approach to Selecting Inexpensive Conservation Storage Solutions *Journal of Conservation and Museum Studies*, 9, pp.4-10.
- Hackney, S., Townsend, J., and Eastaugh, N., 1990. *Dirt and pictures separated: papers given at a conference held jointly by UKIC and the Tate Gallery, January 1990*. London: United Kingdom Institute of Conservation.
- Snaffle, 1894. *Gun, rifle, and hound in East and West*, London: Chapman and Hall.
- Larkin, N.R., 2016. A method to safely move mounted skeletons. *Journal of Natural Science Collections*, 3, pp.29-37.

- Le Mesurier, F.A., 1904. *Memo from Colonel Frederick A. Le Mesurier to Sidney Harmer dated 1904-03-19*. [manuscript], 2:268R. Cambridge, Cambridge University Museum of Zoology Archives.
- Lowe, M., 2014. *Record of Loan between Cambridge University Museum of Zoology museum and Hawk Films Ltd, Kubrick's production company at MGM Studios dated July the 10th 1967*. [email] (Personal communication, 2016).
- McCutcheon's, 2003. Volume 1: Emulsifiers & Detergents. North American Edition. Glen Rock, N.J.: Manufacturing Confectioner Publishing, McCutcheon's Division. In *Conservation*, Supplement 1, pp. 46-64.
- Mori, J.L., 1979. Procedures for establishing a faunal collection to aid in archaeological analysis. *American Antiquity*, 35(3), pp.387-389.
- Powell, M., 2010. Fragile identities: the colonial consequences of CJR Le Mesurier in Ceylon. *Journal of Colonialism and Colonial History*, 11(1).
- Rixon, A. E., 1976. *Fossil Animal Remains*. London: Athlone Press, University of London.
- Santiapillai, C., Wijeyamohan, S., Bandara, G., Athurupana, R., Dissanayake, N., and Read, B., 2010. An assessment of the human-elephant conflict in Sri Lanka. *Ceylon Journal of Science (Biological Sciences)*, 39(1).
- Shipley, A.E., 2011. *"J" A Memoir Of John Willis Clark, Registrar Of The University Of Cambridge And Sometime Fellow Of Trinity College*. Cambridge: Cambridge University Press.